



GLOBAL JOURNAL OF RESEARCHES IN ENGINEERING
GENERAL ENGINEERING
Volume 12 Issue 2 Version 1.0 May 2012
Type: Double Blind Peer Reviewed International Research Journal
Publisher: Global Journals Inc. (USA)
Online ISSN: 2249-4596 & Print ISSN: 0975-5861

Identification of Early Osteoporosis Using Intensity Slicing method

By R. Sivakumar

RMK Engineering College, Kavaraipettai Tamilnadu, India

Abstract - Osteoporosis is a disease characterized by low bone mass and deterioration of bone tissues, leading to bone fragility and, consequently, an increase in fracture risk [2-6]. Loss of bone mass occurs as part of the natural process of aging [4]. Bones naturally become thinner (called osteopenia) as one grows older, because existing bone is broken down faster than new bone is made. As this occurs, the bones lose minerals, heaviness (mass), and structure, making them weaker. With further bone loss, osteopenia develops into osteoporosis. The thicker bones are, the longer it takes to develop osteoporosis. Although osteoporosis can occur in men, it is most common in women older than age 65. Since osteoporosis can develop undetected for decades until a fracture occurs, early diagnosis is important [2].

GJRE- J Classification : FOR Code: 090399



Strictly as per the compliance and regulations of:



Identification of Early Osteoporosis Using Intensity Slicing method

R. Sivakumar

I. INTRODUCTION

Osteoporosis is a disease characterized by low bone mass and deterioration of bone tissues, leading to bone fragility and, consequently, an increase in fracture risk [2-6]. Loss of bone mass occurs as part of the natural process of aging [4]. Bones naturally become thinner (called osteopenia) as one grows older, because existing bone is broken down faster than new bone is made. As this occurs, the bones lose minerals, heaviness (mass), and structure, making them weaker. With further bone loss, osteopenia develops into osteoporosis. The thicker bones are, the longer it takes to develop osteoporosis. Although osteoporosis can occur in men, it is most common in women older than age 65. Since osteoporosis can develop undetected for decades until a fracture occurs, early diagnosis is important [2].

A BMD test is the only way to diagnose osteoporosis and determine risk for future fracture[5]. The painless, noninvasive test measures bone density and helps determine whether medication is needed to help maintain bone mass, prevent further bone loss, and reduce fracture risk. Several different machines measure bone density. Central machines, such as the dual energy x-ray absorptiometry (DXA or DEXA), measure density in the hip, spine and total body. Peripheral machines, such as radiographic absorptiometry (RA)[1], peripheral dual energy x-ray absorptiometry (pDXA). Dual X-ray absorptiometry (DXA) uses two different X-ray beams, due to which there is an increase in exposure to radiation causing harmful side effects. Special types of x-ray machines, are used. These machines are costlier. pDEXA also uses very low doses of radiation, and the results are faster than conventional DEXA measurements. pDEXA has limited usefulness (compared to DEXA) for monitoring the effect of medication used to treat osteoporosis[2]. The PDEXA equipment is much costlier than ordinary X-ray equipment. This method is not recommended for pregnant women because of the radiation exposure to the baby (fetus). Intensity slicing method is proposed to highlight the affected regions in osteoporotic x-ray images in order to assist the doctors in the identification of osteoporosis affected regions which cannot be visually identified.

II. MATERIAL AND METHOD

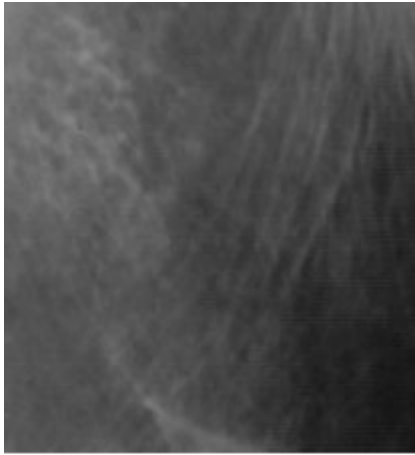
We have made use of X – rays of osteoporotic and non osteoporotic patients at different locations of the body collected from hospitals and processed it using image processing tools of MATLAB.

This method for the detection of osteoporosis consists of two modules.

a) *Intensity Slicing for Bone Structures*

This module is used to highlight pores and the regions that have low Bone Mineral Density, which could be of very great use to the doctors in identifying the affected areas which are otherwise not visually detectable. In this method the radiograph is loaded as bitmap image and converted into gray scale. Then the region of interest in gray scale image is chosen, in order to neglect the black background of the radiograph, the mean is computed for the region of interest omitting the pixel intensities that are less than a scale of 5. This ensures that there is no interference due to the black even if it is accidentally chosen in the region of interest.

The histogram (Histogram plot the pixel intensities in x-axis and the corresponding number of pixels in the y-axis) of the image is computed and stored in a variable, and then the index value of the histogram that has the maximum number of pixels is noted. The size of the region of interest is stored in a variable. Let the index value of the histogram that has the maximum number of pixels be L. Then the pixels with the intensity lesser than the mean value and lie within the range L-10 & L-30 are displayed as red pixels that visually highlight the affected regions. From experimentation it was learnt that the range L-10 & L-30 covers the pixels with intensities which are more prominent in osteoporotic radiographs. The comparison between the histogram of osteoporotic and non osteoporotic radiographs clearly show the reason for the selection of the range in the figures 2.1. -2.4. & Flow Chart 2.5.



OSTEOPOROTIC X-RAY

Figure: 2.1

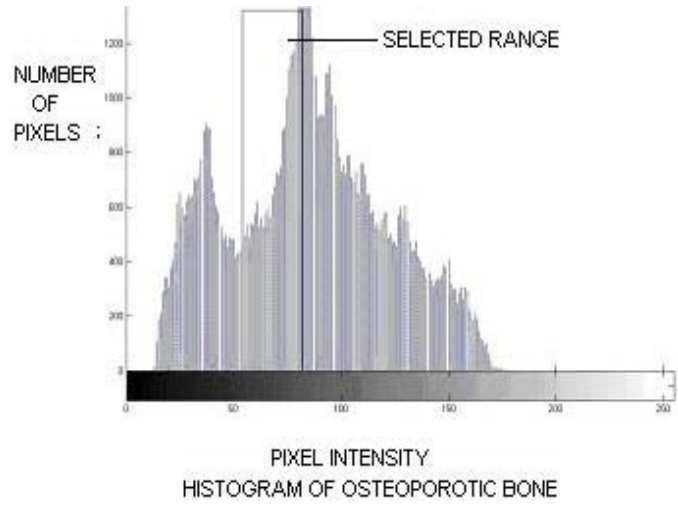
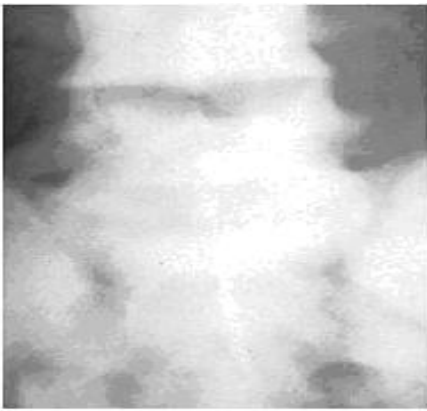


Figure: 2.2



NON OSTEOPOROTIC X-RAY

Figure: 2.3

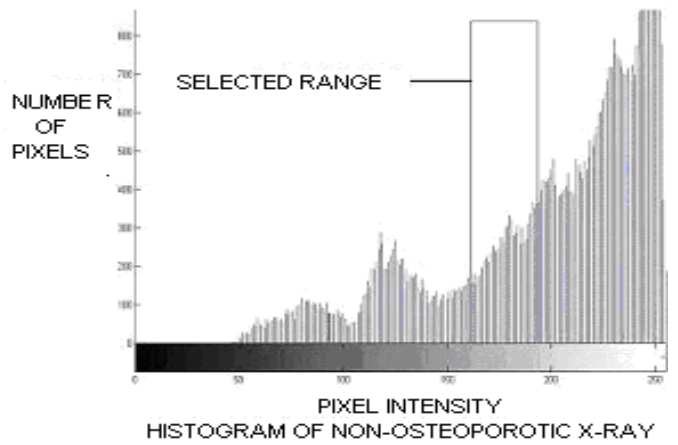


Figure: 2.4



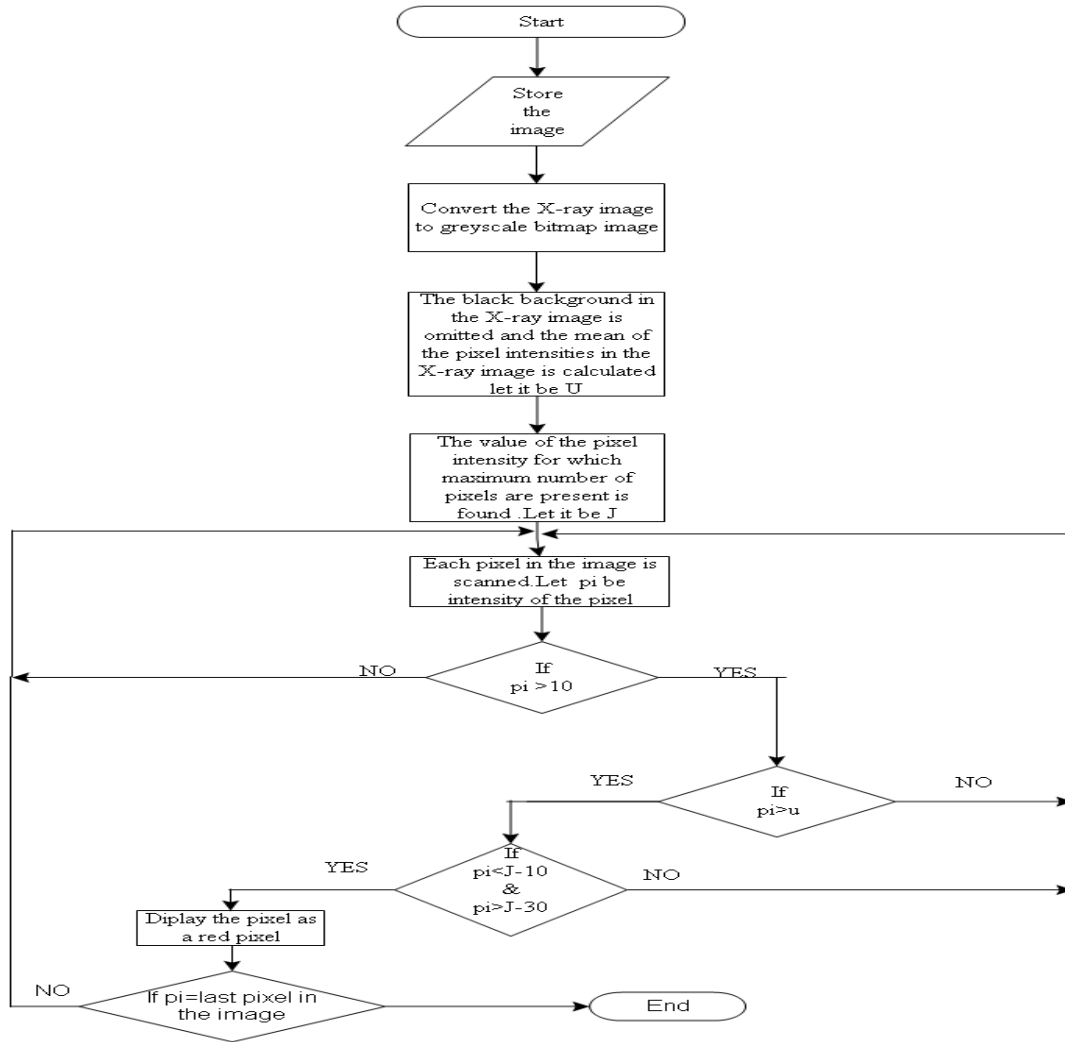


Figure 2.5 : Flow chart for Intensity Slicing for bone structures

b) Intensity Slicing for Tracing Striations

This module is used to highlight striations within the bone structures that have very low calcium deposits, striations are caused due to drastic reduction of Bone Mineral Density. This method for detecting the striations will be of very great use to detect striations which are not visible to the naked eye. In this method the radiograph is loaded as bitmap image and converted into gray scale. Then the region of interest in gray scale image is chosen, in order to neglect the black background of the radiograph, the mean is computed

for the region of interest omitting the pixel intensities that are less than a scale of 5. This ensures that there is no interference due to the black even if it is accidentally chosen in the region of interest. Then the region of interest is fully scanned for intensity variations, this can be done by monitoring the variation of intensities from pixel to pixel. If the variation of pixel intensity is over the threshold value then the pixel with lesser intensity is displayed as red pixel. Consider the following figures 2.6 & 2.7.

145	145	144	140	146	132	160
144	143	141	144	130	145	142
143	144	65	143	125	142	135
142	143	146	130	125	142	146
141	140	126	140	120	143	145
141	143	120	139	142	139	143
142	143	119	141	142	138	142

Figure 2.6 : Pixels before highlighting

145	145	144	140	146	132	160
144	143	141	144	130	145	142
143	144	65	143	125	142	135
142	143	146	130	125	142	146
141	140	126	140	120	143	145
141	143	120	139	142	139	143
142	143	119	141	142	138	142

Figure 2.7 : Pixels after highlighting

If the threshold value is set as 5, then all the pixels which have intensities 5 greater than that of the previous pixel in the same row and pixels which have intensities 5 greater than that of the next pixel in the same row will be highlighted as shown in figure.

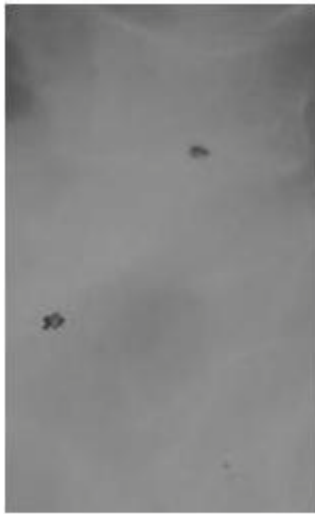
III. RESULTS AND DISCUSSION

a) Results Of Intensity Slicing for Bones

The results of intensity slicing for bone structures are displayed in the following page, figures

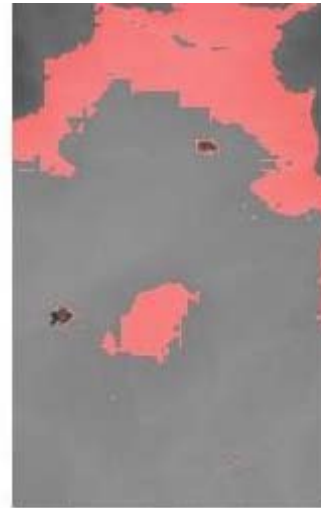3.1, and 3.3,3.5 display the image of the osteoporotic bone and the corresponding outputs of intensity slicing method for bone structures are displayed in the figures 3.2, 3.4, and 3.6 respectively. By examining the osteoporotic images and their corresponding output for intensity slicing method for bone structures it would be clear that, the regions that have low calcium deposits are highlighted clearly. The pores within the bone structures which are hardly visible to the naked eye are clearly highlighted in the outputs

OUTPUTS OF INTENSITY SLICING FOR VARIOUS IMAGES



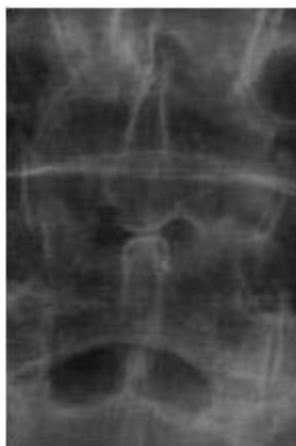OSTEOPOROTIC IMAGE

Figure : 3.1



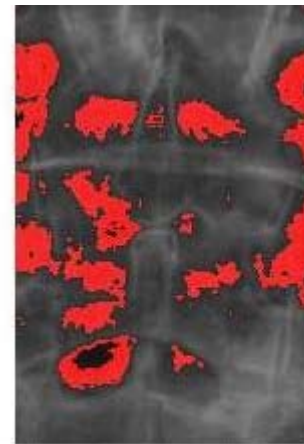
OUTPUT OF INTENSITY SLICING FOR
OSTEOPOROTIC RADIOGRAPH

Figure : 3.2



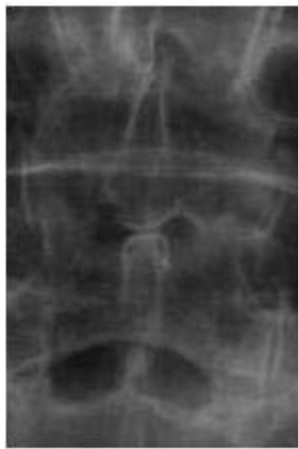OSTEOPOROTIC IMAGE

Figure : 3.3



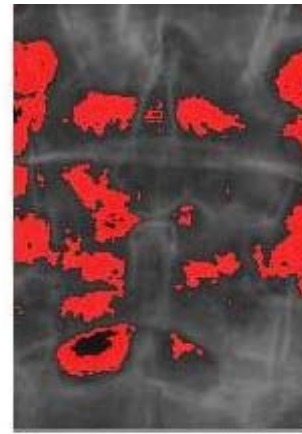
OUTPUT OF INTENSITY SLICING FOR
OSTEOPOROTIC RADIOGRAPH

Figure : 3.4



OSTEOPOROTIC IMAGE

Figure : 3.5



OUTPUT OF INTENSITY SLICING FOR OSTEOPOROTIC RADIOGRAPH

Figure : 3.6

b) Results of Intensity Slicing for Tracing Striations

The results of intensity slicing for tracing striations are displayed in the following page, figures 3.7,3.9,3.11 display the image of the osteoporotic bone with striations, the corresponding outputs of intensity slicing method for tracing striations are displayed in the figures 3.8,3.10,3.12 respectively. By examining the

osteoporotic images and their corresponding output for intensity slicing method for tracing striations, it would be clear that, the regions having low calcium deposits are highlighted clearly .The striations within the bone structures which are hardly visible to the naked eye are clearly highlighted in the outputs .

OUTPUTS OF INTENSITY SLICING FOR VARIOUS IMAGES

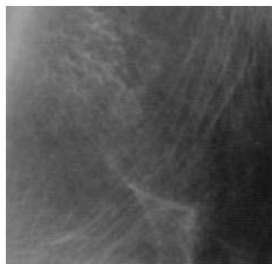

Figure 3.7 : Osteoporotic X-ray 1



Figure 3.8 : Osteoporotic X-ray image 1 with striations highlighted



Figure 3.9 : Osteoporotic X-ray 2



Figure 3.10 : Osteoporotic X-ray image 2 with striations highlighted





Figure 3.11 : Osteoporotic X-ray 3




Figure 3.12 : Osteoporotic X-ray image 3 with striations highlighted.

From the analysis of various radiographs using Intensity Slicing method produce accurate results. Thus using this method, detection of osteoporosis can be done with a minimum exposure to radiations and it can be of very great use to the doctors in the analysis of x-ray images for detecting osteoporosis.

REFERENCES RÉFÉRENCES REFERENCIAS

1. Majumdar S, Lin T, Link TM, Millard J, Augat P, Ouyang X, Newitt D, Gould R, Kothari M, Genant HK (1999): "Fractal analysis of radiographs: Assessment of trabecular bone structure and prediction of elastic modulus and strength". Medical Physics, VOL 26: PP1330-1340.
2. Wahner HW and Fogelman I. "The Evaluation of Osteoporosis: Dual Energy X-ray Absorptiometry in Clinical Practise", Martin Dunitz Ltd., London, 1994.
3. Mengko TR and Pramudito JT. "Texture analysis of Femur Radiographs for Osteoporosis Assessment," WSEAS Transaction on Computers 2004; 3: 92-97.
4. Osteoporosis: Pathophysiology and Clinical Management By Eric S. Orwoll, Michael Bliziotes Edition: illustrated Published by Humana Press, 2003.
5. Pierre J. Meunier "Osteoporosis: Diagnosis and Management", Taylor & Francis, 1998.
6. Hong-wen Deng, Yao-zhong Liu "Current Topics in Osteoporosis", World Scientific, 2005.

